MCQ

1. Strabismus is a common presentation of ureteric stone, it means
a. haematuria
b. aching pain
c. difficulty with voiding urine
d. urinary retention

2. Concerning bile content.
a. chenodeoxycholic acid
b. Lecithin
c. Taurine
d. CCK

NB Bile contain – cholesterol, lecithin, bile pigments (Bilirubin, biliverdin), salts of bile salts of acid (Na glycholate or Na glycocholate, taurocholate), small amount of Cu and phospholipids

3. Concerning ureteric stone (highest)
a. Calcium oxalate is commonest
b. calcium phosphate
c. Aluminium phosphate
d. urate

NB about 95% stones radio-opaque.. alkaline urine ppt Ca stones but acidic urine ppt urate and cystine

4. Concerning stone
a. Calcium oxalate requires acidic medium
b. urate require acidic urine
c. urate requires alkaline urine
d.

5. Concerning Renal Ca
a. Adenocarcinoma is the commonest (80%) ✓
b. Squamous Ca is the commonest
c. Transitional is the commonest
d. None of the above

6. ureteric colic
a. located in the costal margin
b. it has fixed site at the lumbar
c. The pains radiates to the tip of the penis

7. Concerning Diagnostic peritoneal lavage (DPL)
a. +ve if > 100,000 RBC
b. +ve if 200 WBC aspirated
c. 150 RBC aspirated
d. 150 WBC aspirated

NB +ve if
WBC > 500/ml
RBC > 100,000/ml
Amylase 75 IU/ml or 150 ml/dl
– food, bile, bacteria

8. The bile duct enters
a. 2nd part of the duodenum
b. 3rd part of duodenum
c. head of pancreas

9. Concerning hirschsprung's
a. Suction biopsy is diagnostic
b. Barium is diagnostic
c. Manometry
d. full thickness biopsy is the most diagnostic

10. Concerning Intussusception
NB proximal telescope into distal (mf 3:2)
Peak periods between 5-10 months and gradually decline at around 18 months of age.
It is the commonest cause of intestinal obstruction in patients 5 months - 3 years of age. Accounts for 25% of abdominal emergency in under 5yrs.
Take note of Dance sign.
Ileocolic is the commonest site of intussusception
others sites are ileoileal, ileoileocolic

11. 45 year old woman with breast mass what's the most likely diagnosis
a. fibroadenoma
b. fibrocystic
c. intraductal papilloma
d. Breast cancer

12. Concerning Duke's classification
a. Severity based on presentation of colon wall
b. degree of anaemia
c. size of tumor

NB A - confined to bowel wall
B Through wall into surrounding tissue
C. lymph node involvement
D - distant metastasis

13. Anaemia in colorectal CA is common in
a. Right colon NB Nutrient absorption.
b. left colon
c. Sigmoid colon
d. rectal colon

NB left side has common presentation of CA in decreasing order
rectum, sigmoid, caecum,

14. Which of these does not cause PUD
a. H. Pylori b. hypocalcemia c. hypercalcemia
d

15. Concerning H-pylori a. Cause gastritis b. Duodenal ulcer c. Gastric ulcer d. Curling ulcer

16. Concerning pancreatic Ca
a. pancreaticojejunostomy is curative option.
b. Whipple operation is curative in most cases
c. Whipple operation is not curative

17. Concerning shock patient w2 is most inappropriate
a. face mask to ventilate b. Give NS c. Give blood immediate d. Nurse in headway 30° position??

18. Concerning a girl brought in c/o of sex dimorphism which of these is inappropriate urgent mgt
a. K+ level estimate b. Karyotyping ?? c. Urs

19. Concerning anorectal fissure
a. most seen at 6 o clock
b. fistulectomy is curative operation

NB mostly seen at the posterior site. With perineum, phallus in front for 12° clock and low post.

20. Concerning splenic rupture
a. Kehr sign is positive because of irritation of diaphragm
b
c
d.

NB

21. Concerning Acute pancreatitis
a. always contain calcium
b. Shock always present
c.

NB ppt ca causing saponification
complication) Br C, Arf
Diabetes, malena.
pancreatic necrosis,
pseudocyst

22. Concerning acute appendicitis
a. Best diagnosed by history and Examination
b. diagnosed with USS
c. Diagnosed with Abxray

23. Concerning Acute appendicitis
a. pain comes before vomiting
b. vomiting comes before pain — NB points to obstruction
c. vomiting and pain come together
d.

NB MAN TREEL
migrating pain, Anorexia, Nausea + vomiting, Tenderness at Rif or McBurney, rebound pain, Elevated leucocyte elevated temp

24. Hernia with Meckel diverticulum
a. Littre's
b. Patalon
c. Spigelian
d.

25. Concerning Acute pancreatitis except
a. Cullen's sign b. Grey turner sign c. Shock
d. Angel sign

26. Concerning pancreatectomy complication
a. Sjorgren syndrome b. Frey syndrome
d.

NB Code for Horner's syndrome SAMPLE
Sympathetic involvement, Anhidrosis, Miosis
P — ptosis L — loss of sweating E — Enophthalmos (not Exophthalmos).

27. Concerning Submandibular gland
a- produce more serous secretion than parotid
b. has lesser risk of cancer
c.

Pls read up like 4 question come out from it.

28. Concerning Colorectal ca (certain)
a. more common in left
b. commoner in right
c. has less risk of malignancy (NB has highest risk ~~[illegible]~~)

29. Concerning obstructive jaundice
a. Acid phosphatase markedly raised
b. γ-Glutamic acid is used to differentiate edema from intrahepatic causes

30. Concerning inflammatory stricture
a. usually multiple
b. usually singular
c. usually occur 2 months post infection and dilatation for single ca
d. usually takes a year to develop.

NB in multiple causes the best opt is urethroplasty

NB always ask for sexual Hx in pt with difficulty in urination

31. Concerning inflammatory stricture
a. substitutive urethroplasty is the last option
b. best treated with urine diversion
c. dilatation of the urethra is the best treatment

NB Buccal mucosa is best urethroplasty because of its secretory nature.

32. Gaitin catheter is
a. best used to dilate urethra in female
b. self retaining catheter
c. best used to catheterize female
d. used to correct stricture in male

33 Commest cause of respiratory distress post thyroidectomy
a. Tracheomalacia
b. Tension haematoma (neck wound of retrosternal hematoma)
c. laryngeal oedema
d. RLN damage.

34. In UITH herniorrhaphy repair is commonly done by
a. modified Bassini repair
b. Shouldice
c. Mesh repair
d. endoscopic

35. Hernia of those can not be operated endoscopically
a. hernia b. RCC c. bladder exstrophy
d.

36. Contraindication to catheterization
a. bladder injury b. penile bleeding
c.

37. A 60 y with back pain, lower urinary symptom and weakness of leg on Examination
a. DRE b CXR c AXR

38 Man with terminal haematuria suspected to be schistosomiasis what investigation
a. cystoscopy and biopsy
b. IVU c. cystourethrography d. shift

39. Concerning thyroid
a. papillary is the commonest CA
b. medullary is commonest
c. follicular is commonest
d. lymphoma is more malignant.

NB papillary is commonest but follicular is commonest in endemic region like Ghana and Nigeria.
Mean up the % of occurrence

40. Why these is the most difficult to differentiate from benign form
a. medullary b. lymphoma c. follicular d. papillary
NB

41. Why these thyroid will become malignant on exposure to radiation a. medullary b. papillary c. lymphoma d. follicular

42. Concerning anorectal malformation
a. type III has V shape b. type IV has dimpling appearance c d

43. Small bowel intestinal obstruction is best diagnosed
a. Barium meal and follow through b. Barium enema c. Manometry

44. Intussusception in 4 yrs is best treated by
a. hydrostatic reduction b. pneumatic reduction
c. resection ?? d

45.
a. Ladd operation
b. hydrostatic reduction
c. pneumatic reduction

46. wrong that is not an Emergency
a. Acute appendicitis b. hirschsprung
c. Intussusception d. Malrotation of gut.

47.
a. Enterocolitis is seen in term infants
b.

48 Man with diverticulosis at colonic colon and hepatic flexure is best treated by
a. right segmental diverticulectomy
b. right hemicolectomy
c. left hemicolectomy
d. Ant resect

N.B
Extended Right hemicolectomy
Transverse is done

49. epididymis and vas deferens are derivatives
a. Mesonephric b. Metanephric c. Müllerian duct

50. wrong that is not a cause of inguinal hernia
a. hirschsprung b. Inguinal undescended testis
c. Intussusception d. Marfan Syndrome e. Meconium ileus

51. A man with advanced prostatic ca is best treated by a. retropubic prostatectomy
b. unilateral orchidectomy
c. Testicular antagonist

NB Bilateral orchidectomy, Hormonal therapy & radiotherapy.

52. Concerning omphalocele with macroglossia
a. hypoglycaemia NB trunk Beckwith-Wiedemann Syn.
b. hyperglycaemia c. hypertension d. hypokalaemia

53. A 4 year boy with nose mother bleeding and palpable mass at left flank
a. Wilms b. polycystic kidney c. lymphoma

54. 7 year girl with bleeding per vaginum most likely cause
a. vagina Sq Ca b. lymphoma c
NB - Cervical/uterine Sarcoma
- hypothyroidism
- hyperprolactinemia, cervicitis, precocious puberty. PITC.

55. 4 yr old with haematuria & flank mass
a Wilms b polycystic kidney Sx
c lymphoma

56. Most common bronchial cyst anomaly
a. 1st b 2nd c 3rd d 4th

57. Concerning epispadias
a. dorsal meatal opening with ventral chordee
b. ventral meatal with dorsal chordee
c. never possible in female
d. dorsal meatal opening with dorsal chordee

58. Woman after hysterectomy had urinary incontinence but still feel urge to urinate
a. urge incontinence b. uterovaginal fistula
d. vesicovaginal fistula

59. In large intestines
a. Commonest seen in Xray
b. haustral markings seen in Xray

60. Recurrent ulcer caused by
a. Incomplete vagotomy
b. Zollinger Ellison syndrome
c. hypercalcemia d. ULD

61. Woman with 7/7 Hx of fever, 4/7 Hx of ~~abdo~~ generalized abd pain and Hx of abd distension
a. Perforated typhoid b. perforated or ruptured appendicitis c. ruptured ectopic pregnancy
d.

62. Frontal Adenomatous polyposis
a. benign tumor
b. occur more in female
c. has malignancy potential in the first decade
d.

63. Concerning the above we is not associated with a. desmoid tumor b osteoma c sebaceous cyst d. epidermoid cyst.
~~Gard~~ NB Gardner syndrome
Desmoid tumor, osteoma and Multiple sebaceous cyst

64. Concerning a px with harmatoma we of this want be included to the px.
a. ulceration potential b. constipation c bleeding
d. Infiltration

65. A pt complains of central pain that radiates to the RLQ most likely diagnosis
a. Acute appendicitis ??
b. Acute pancreatitis
c. Intussusception

66. Concerning Bladder Ca (Squamous Ca)
a. prolong indwelling catheter can cause this just as schistosomiasis

NB Transitional bladder Ca is the commonest infection and irritation will cause sq cell Ca of the bladder.

67. Concerning A 50 year old woman who had head injury and was given mannitol
a. to reduce ICP b. To improve venous return

68 Concerning T4 breast Ca in 50year old woman in UITH WR is inappropriate.
a. Chemotherapy b. radical mastectomy
c. Immunotherapy d. Radiotherapy e. psychotherapy

69. Matching - WR is wrong
a. pubic osteitis

NB pubic osteitis is a non infectious inflammation of pubic symphysis

70. wc of these ca needs CXR, skull xr pelvic x-ray.
a. RCC b. Prostate ca c. Testicular
— All will need US abd

71. Concerning Testicular ca
a. Seminoma is the most common
b. ~~Test~~ Teratoma is the most common

72. Concerning colorectal ca.
a. Dukes stage 3 you will feel Blomberg shelf on DRE
b. All adjacent structure are removed to enable cure
c. Anastomotic structure have no occurrence

73. Contraindication to circumcision
a. epispadia
b. para phimosis
c. phimosis

NB others are
- hypospadias
- Bleeding dyscrasia ie coagulopathy
- prematurity

74. Seminal fluid release is due
a. sympathetic and somatic nerves
b. parasympathetic stimulation
c. somatic activity.

NB point — Erection (parasympathetic)
shoot — Ejaculation (sympathetic)

75. Laparotomy in UTH
a. pt hair is ~~shop~~ shaved with sterile stapler and sterile gloves
b. hair shaved on the operating table
c. hair shaved a night before surgery

76. Concerning Breast Ca in UITH
a. Single interval chemotherapy in courses
b. Combination cycle of chemotherapy
c. Continuous single chemotherapy
d. Continuous combination chemotherapy

77. Concerning Splenectomy
a. Viral infections occurs most after post Splenect
b. best due hereditary spherocytosis
c. best treatment in splenic rupture

78 Concerning villous papillomata
a. may be hereditary
b. Can be diagnosed on inspection and papillomata

79. Concerning urinary stone formation
a. vit C and D b. ~~Ca~~ Increase citrate

NB Risk factors: Ca, Na, uric acid, oxalate, cystine
dehydration, obesity

80 Concerning anorectal Malformation (ARM)
a. is associated with Eclampsia b. associated with hypertension

81 Concerning omphalosis association in syndrome
a. hemihypertrophy b. Beckwith wiedeman syn

82. Boy had difficulty in passing urine but catheter was passed with ease most likely diagnosis
a. posterior urethra valve b. urethra stricture
NB When urinating the valves come together

83. Best agent to use in GFR estimation in hospital
a. Inulin b. Creatinine c. urea d.
NB Inulin is for research purpose as it is expensive

84. A pt had distended bladder and urinary retention. A doctor during suprapubic cystostomy must watch out for
a. postrelief diuresis
b. diverticulae of the bladder
c. post obstructive diuresis
d.

85. A doctor attending to HIV+ pt had a needle prick injury what percentage of transmission of infection does he have
a. 0.3% b. 30% c. 6% d. 60%

86. Health practitioner or paramedic not susceptible to HIV infection is a General surgeon b microbiologist c nurses d. haematologist

87. Most common lead point in intussusception in children
a. Meckel diverticulum
b
c

88 Most common early complication of inguinal hernia repair
a. scrotal oedema b. recurrent hernia c
d

89. The commonest symptom in tuberculous arthritis is a dysuria b frequency c nocturia d urgency
NB Gonococcal arthritis occurs 2-10 days after exposure and septic occurs 20-30 years after it. While the Gonococcal arthritis takes 3-4 weeks for presentation chlamydia is the commonest

90. Which of these is a common presentation of Acute abdomen in children
a Acute appendicitis b Acute pancreatitis c salpingitis d. Typhoid perforation

91. The most common cause of post-op pyrexia (48hrs)
a - UTI from catheterization b deep vein thrombosis
c Atelectasis
NB 5 causes of post op pyrexia
1. Wind - Pneumonia, atelectasis, aspiration, pulmonary embolism 1-2day
2. Water : UTI related to indwelling catheter 3-5 days
3. Walking : DVT and pulmonary embolism 4-6 days
4. Wound SSI 5-7days
5. Wonder drugs or what did we do - drug fever related to interventions 7days +

92. Which of these is not a source of HIV transmission
a Saliva b pus c blood d vaginal secretions

93 Which of these is a sclerosant used in cystic hygroma a Bleomycin b Cyclophosphamide
NB Bleomycin, and hypertonic glucose are used
OK 4,3,2

94 A child who has circumcision and started bleeding 5 days post op
a. Haemophilia b. Stopping of placebol

95. Veins associated with use of the following exep
a. Denny-Brash
b. Beckwith Wiedemann

* * * * * * * * * *

96 Nasal allergy is an example of use hypersensitivity
a. Type 1 b Type 2 c Type 3 d Type 4

97 Advantage of Focused assessment sonography for Trauma (FAST)
a non invasive b less expensive c can pick fluid less than 100mls d

98 use of there is not metabolic response in injury
a ↑ T_3 T_4 b ↑ cortisol c ↑ adrenalin d ↑ glucose
NB Ebb phase < 36hour
flow phase
catabolic < cortisol adrenergic 3-5day
cortisol withdrawal 4-7days
Anabolic phase 1-3weeks

99 A px with bleeding per rectum on defecation after constipation, pain in the rectum with bean like mass lesion on rectum, use is most inappropriate a Soft with hypertonic saline b softening of stool with hyperosmolar paraffin c

100 Concerning rectal Ca
a early diagnosis by FOCB b proctosigmoidoscopy
is diagnostic c Colonoscopy + biopsy most appropriate

101 Faecal occult blood is
a. used for early diagnosis of colorectal Ca and
can pick about 94% of cases
b it is highly specific
NB pls read it up because its questions can be
confusing

102 Thick walled cavitation is associated with
a. Tuberculosis b lung abscess c bronchogenic Ca

103 Torsion # wc of these
a b medical treatment

104 Wc of these is late fx of thyroidectomy
a hypothyroidism b parathyroidism c tension headache
d tetany

105. A driver in a vehicle with seatbelt had accident
wc of these is not a likely presentation
a right clavicle # b. left clavicle #
c. hepatic rupture d. splenic rupture

106 Fromnet sign used to test a ulnar nerve
b radial nerve c median nerve d sciatic
nerve
NB in fromnet sign the thumb fails to
adduct but flexes instead. The adductor
pollicis paralysis causes this and the flexor pollicis
longus flexes.

107 Mc Ewen triangle
a. used for mastoid cortex surgery
b. c d
NB it is formed by zygomatic arch, post wall of the external acoustic meatus

108 Bilateral fluffy opacity is a fx of a
a. lung collapse b pulmonary fibrosis c pulmonary agenesis d pulmonary oedema

109 Unilateral elevation is a fx of except
a pulmonary infarction b pulmonary agenesis

110 Content of Membranous labyrinth
a endolymph b perilymph c csf d none of the above
NB Bony labyrinth — perilymph

111 Ominous symptoms in urology
a frequency b urgency c haematuria d dysuria

112 A registrar elected van Zant sign in a px known cocaine addict while the other reg said is due to abdominal tiger, the px had abdominal pain but the senior reg said both were correct, so which is a poor prognostic factor
a > 2 mmol of Ca b hyperglycaemia > 10 mmol/L
c age > 55

NB

Ranson's Criteria
- HSBB for within 48hrs
- Ca^{2+} < 2mmol/L 8mg/dl
- Haematocrit PCV > 10%
- PaO_2 < 8kpa 60mmHg
- base deficit > 4
- Serum urea N > 16mmol/L

Code Georgian Law (GaLaw) for within 24hr of Presentation
- G-Glucose > 11mmol/L or 200mg/dl
- AST > 250IU/L
- LDH > 350IU/L
- Age > 55
- WCC - > 16x10^9/L

NB A comes before L so AST before LDH check the figures

113 Wic of these will cause haematuria
a testicular tumour b inguinoscrotal hernia

114 Supracondylar fracture can result in except
a vascular necrosis b median nerve palsy
c cubitus varus d cubitus valgum
NB Cubitus varus, Ischaemic contracture

115 Erb palsy
a. waiter drink b abduction of hand
c physiotherapy resolves it in most cases
NB waiter's tip, addiction, extend of the fore hand pronation

116 cystic hygroma a multiloculated tumour
b. originate from 2nd brachial cleft c. originate from 3rd brachial cleft and mostly on the right d its is a lymphatic obstruct
NB usually on left

117 Clavicular # wk of the except
a Arm sling b. Shoulder spica c figure 8
d ORIF – on table Presentation
Cool day – All are used below

118 Px known hypertensive with congestive heart failure with intestinal obstruction is categorized or classified by American Society of Anaesthesiologists as
a. 2E b 3E c 4E d 5E
NB 1 – healthy px no limitation
2 – mild systemic dx with mild limitation
3 – moderate systemic with moderate limitation
4 – life threatening systemic dx
5. Moribund
6 – Brain dead
E – Emergency

119 wk of these anaesthetic does not undergo metabolism
a. Mivacurium b atracurium c. rocuronium
d. pancuronium NB Doxacurium also

120 New anaesthetic with high lipid solubility a high potency b fast onset of action c prolong duration of action

121 All lipid soluble anaesthetic have cardiovascular depression wk of these has least
a. Desflurane b Isoflurane c Sevoflurane
d- halothane
Sevo – children surgery NB
Iso – neuro / opthalmic surgery because of least vasodilatation.

122 Why these can not be diagnosed via plain radiograph
a. oesophageal atresia b duodenal atresia
c Hirschsprung ??

123 Concerning breast Ca
a. 95% occur in female b 4% risk of lifetime occurrence in female c 1% risk in every year d

124 Commonest breast tumour is
a fibroadenoma b breast ca c phyllodes tumour

125 Why these is not being benign colon tumor
a. lymphoma b leiomyoma c lipoma d adenoma

126 Concerning lymphangioma except
a. Surgery b irradiation c chemotherapy
d. cryotherapy.

127. prophylactic antibiotic can be given
a clean b clean contaminated c contaminated
d. dirty

128 A Px with abd pain, obstruction, nausea and non bilious vomiting of stalled food we of these want you expect on upper GI endoscopy
a. haemorrhage b gastric ulceration and deformity
c. inability of endoscope to move into the duodenum d. stale of food

129. Spinal shock
a. resolves 24-48 hrs

130 Most commonly injured vertebra a. Lumbar
b Cervical c thoracic d sacral

131. Complete transection
a fecal incontinence b. urine incontinence
c. fecal and urine incontinence d None of the above.

132 MC of the sx is not incomplete transection
a. Brown Sequard b Central cord syndrome
c post. d Central

133 Quenfey uroplasty involve using
a. Buck's fascia b Tunica albuginea c Dartos fascia

134 Best for substitution urethroplasty a Buccal mucosa b bladder mucosa c rectal mucosa

135. Commonest precursor of vit A
a. retinol b α-Carotene c β-Carotene
d. vit C
Read up clinical eye fx in vit A Defn

136 All of these will accept if partial gastrectomy + Billroth II operation
a. Alloxan syndrome b Short bowel syndrome
c. Short stomach syndrome d. post vagotomy syndrome
Billroth I — gastroduodenostomy
NB Billroth II — gastro jejunostomy

137 Pancreatitis
a. steroid and therapy for chronic pancreatitis

138.

apex left ventricle
Right border - right atrium
left border left atrium and part of ventricle
Sup. border left atrium and great vessels
Inferior border left ventricle and right ventricle.

- Inf border is diaphragmatic surface
- Sup. border serve as base

139. left patent ductus arteriosus, primary venous return
a. left coronary ~~patent~~ ~~ductus~~ arteriosus, right primary venous return
b
c
d.

140 26yr old pregnant lady with decalcified cellulitis mastitis best treatment option
a-5 FU and methotrexate b IV doxorubicin c. IV metronidazole + Fluconazole d IV amoxicillin e IV metronidazole + ceftriaxone

141 appropriate Rx of a fungating breast ca
a. Combination chemotherapy b immunotherapy c radiation d mastectomy

142 Concerning clavicular # in Newborn
a- associated with subclavian rupture
b: associated with brachial plexus injury

143 wc of these is not a fx cellulitis
a red warm skin b Muscular necrosis

NB is a non necrotizing inflammation of the skin and subcutaneous tx

144 30 year old lady presented with fever with no chills now right abd pain of 10/7 duration and abd distension of 4/7 wc is the most likely diagnosis
a perforated appendicitis b perforated Typhoid
c ovarian cyst torsion

145. Neovascularization after a graft in a burn px can be checked via the skin colour after a. 1st day b 2nd day c 3rd day d 4th day e 5th day ??

146 Acute intestinal obstruction pain
a. continuous pain b waxes and wanes

147. Investigation to confirm haematuria a urine microscopy b Abx. c urea and creatinine

148 posterior urethral valve a Renal failure is rare b Resection and anastomosis the treatment c enuresis a poor prognosis

149 wc of these is used to assess prognosis of post. urethral valve a a b urea c Na d. creatinine

150. The ff investigations are done in haematuria except a. Abd pelvic USS b. IVU c. CT d

151 Ascending colon Ca Tx a right hemicolectomy b. ileo colectomy c. Anterior resection d. Abdominoperitoneal resection

152 Annular and proliferative type of polyp is common in we find a right colon b. left colon c. sigmoid d. transverse

NB Commonest type is adenocarcinoma and commoner in female but rectal is 2x in male. Annular type present with obstruction (diarrhoea alternating with constipation) in left.

153 50 year old man presented with constipation, spurious mucoid diarrhoea + intestinal obstruction a. cauliflower b. polypoid c. ulcerative d. annular

NB right has higher rate of anaemia and palpable mass ulcerative

b. Sigmoid Ca give spurious diarrhoea.

The left side is associated with obstruction and colicky pain

154 Commonest cause of lower GI bleeding a. colorectal Ca b. haemorrhoid c. rectal Ca

155. A 30yr. fulani man presented with right iliac fossa mass we of these is not likely diagnosis a. Amoeboma b. bilharziasis c. appendical mass DD appendical mass abscess, caecal wall tumour amoeboma, crohn

156. Carcinoma of the anus
a- most squamous b c d

NB
Most common is epidermoid (squamous cell ca)
always ask of history of haemorrhoids and perianal abscess. Adenocarcinoma occurs in the upper part

157. Ca of the rectum
Read it up. GI questions can be crazy at times

158. Most diagnostic test for Pilo a + ray b cystoscopy + urogram

159. Indication for immediate laparotomy in penetrating abd injury except.
a. unstable vital sign b No evisceration c. diaphragmatic injury

NB are
- vital sign instability
- peritoneal sign
- diaphragmatic injury
- Evisceration
- intra abd haemorrhage

159 Adenocarcinoma of the colon
a follows adenomatous sequence
b. Most occurs in the first 10 yrs

160 Advantage of mechanical prosthetic over biological valve a. more durable b gives metallic click and makes pt feel special c. requires frequent lifelong anticoagulation

161 Complication of PUD with highest mortality
a perforation b bleeding c deep penetration

162 Common cause of ling segment stricture
a. perineal trauma b inflammation c instrumentation
NB Bulbar is the most common site of stricture

163 Use of vit A
a- carcinogenesis b hearing

164 Mandibular #
a. Commonest cause is motor bike accident
b. No teeth involvement

165. Dental caries
a odontogenic infection b no infection c. aetiology is unknown

166. Cumbined study is used in a BPH b UTI
c haematuria d PUV

167 Tangential excision is done in use degree burn a. 1st b 2nd c 3rd d All of the

168 Commonest cause of burn
a. irradiation b flame c chemical d hot fluid

169 Use of these should not cause otitis media
a- p. aeruginosa b. moraxella catarrhalis
c. strep pneu d H. influenza

170 Late obstruction will lead to hyperviscosity

171 If involving only 1/3 of free nasal bridge ~~contact~~ maxillary sinus, orbit and external ear a. Le fort I b. Le fort II c. Le fort III

172 Concerning the caecum with a bleeding tendency

173 Wx is of choice is appropriate for inguinal hernia repair in adult
a. Magpie bassini b. Mesh repair c. Increased NB

174. Ca of the caecum presents with a. Hepatomegaly b. GI lower tract c. d

175. Abd distension 2° to intestinal obstruction
a. No secretion proximal to it
b. Acid metabolism
c. hypovolaemia
d. hyp
Le fort I
NB flattened palate — upper dental ridge nasal opening, inf nasal septal
Le fort II — inf border rim, nasal bridge pyramidal
Le fort III Ear involvement
Check out the pic pics

176 In intestinal obstruction with abdominal distension a. no secretion proximal to it b. no absorption proximal to it c. hypovolaemia d. acidosis (metabolic) e. hyperkalaemia

177 Which of these will you not elicit in blunt abdominal injury
a. Kehr sign b. Ballance c. Angel sign d. Cullen sign

178 TNM staging of Gastric Ca T3
a. Tumour 7.5cm ~~in muscularis propria~~
b Tumour in Muscularis propria
c Tumour in at serosa
d. Tumour exit serosa to surrounding tissue nodes
e. tumour metastasis to liver

T_1 - invade submucosa
T_2 - invade muscularis propria
T_3 subserosal or beyond
T_4. adjacent or ~~perforate~~ visceral

179 A pt presented with intestinal obstruction, distension of abdomen, empty rectum with no peristalsis (pt paralytic ileus) wc of these is not likely
a. Slurred speech b. Inverted or tented T wave c presence of U wave d

NB ~~Pt~~ of hypokalaemia
PR - prolong PR interval
ST segment depression
Inverted T or flattened T wave

180 Post thyroidectomy pt presented with respiratory distress and swelling site with blood wc is the most appropriate treatment
a. removal of stitch in layers and removal of haematoma - (tension haematoma)
b. Take to ICU for intubation (probably tracheomalacia)
c Steam inhalation (laryngeal oedema)
d. Give $CaCl_2$ - hypocalcaemia

181 A known Kriic smoke and alcoholic was going for operation wc of these is correct
a. Take or give higher dose of anaesthetic because he has increased liver enzymes
b. Anaesthetic should be reduce because he has reduced liver function
c He has high risk of bronchospasm
d. He should be weaned off alcohol and smoking for a year then do the operation

182 A known hypertensive on antihypertensive and antiplatelet (aspirin) wc is correct
a. Stop aspirin 7 days to surgery
b. Take antihypertensive in morning of surgery
c should not take antihypertensive morning of operation
d Should not take both drugs for 7 days before surgery
NB Etomidate is the most preferred in hypertensives.
Avoid ketamine
In DM pt surgery should be 1st on the list because of fear of hypoglycaemia and missing dose of insulin be skipped

183 high fistulo in ano is best treated by
a fistulectomy b fistulotomy c Mechanical
d Seton procedure

184. Anal fissure is common in post aspect of anus

185 In a px with acid distension and hypovolemia we of these must give
a. 5% dextrose H_2O b 4.3% dextrose saline
c 10% dextrose saline d Ringer lactate

186 An obesed px with dull, boring pain in the right hypochondriac with mass that give hypoechoic shadow in USS we incision will be used a. upper midline incision b Rutherford incision c Lanz incision

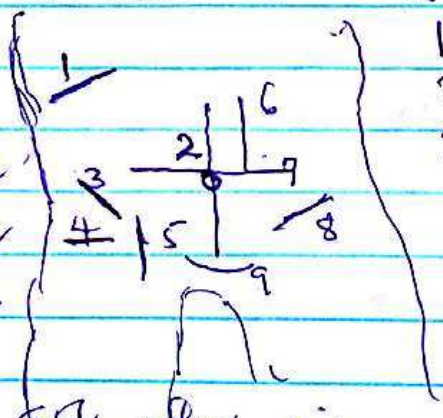

1 Kocher incision
2 midline incision
3 McBurney or Gridiron incision
4 Lanz incision
5. Battle incision
6 Paramedian incision
7 Transverse incision
8 Rutherford Morison incision
9. Pfannenstiel suprapubic incision

In obesed px the midline is preferred for wider access in surgery.
They can pick this in pre test.

187 papilloedema is indication a for emergency intervention
b of raised intracranial pressure
c of mechanical ventilation

1. WC of these is late complication of thyroidectomy
a hypothyroidism b parathyroidism c tracheomalacia d haemorrhage e tetany

NB Early complication
- Reactional haemorrhage
- Tracheomalacia
- RLN palsy
- hypoparathyroidism
- SSI
- ~~Lactic~~

Late
- hypothyroidism (12-18 months)
- Scar formation
- keloid / hypertrophic

2. Braca I and II gene in breast ca are located a Xsome 17q and 13q respectively b Xsome 17p and 13p respectively c Xsome c Xsome 21q and 18q d Xsome 21p and 13p

NB p — is short arm
q — long arm

3. Na^+ content of Ringer lactate a 130 b 80 c 150 d 121

4. K^+ content of Ringer lactate a 4 b 3 c 2 d 10

5. Cl^- content of Hartman solution
a. 111 b 54 c 150 d 130 e 21

6 Oring's procedure (oesophagectomy)
Indication — oesophageal ca, achalasia, constriction

7. Heller's procedure (cardiomyotomy) — Achalasia
NB Heller — Achalasia
Oring's — Oesophage ca

8 Septic arthritis
a. Caused by viral infection
b fall from height
c chemical
d. None of the above

9. Use of these is done in clavicle
a Figure 8 cast

10 use of these is used for calc area of burn both in adult and children a Wallace chart b Lund and Browder's chart
c d

11 Rule of 9 in burn is credited to a Wallace b Browder c Lund d university of Edinburgh
NB b Lund and Browder chart the head ~~has~~ change is taking into consideration.

12 Early diagnosis of rectal ca may be a. Fecal occult blood estimation b. Barium enema c Abdominopelvic USS d Proctosigmoidoscopy Examination 2?

13 Submandibular gland a deep to mylohyoid b tumor more likely to be malignant than parotid c uncommon site for sialolithiasis
NB ~~part~~ parotid — more neoplasm
Submand duct more stone formation because of mucous secretion

14. Commonest Neoplasm in pancreas
a. pleomorphic b c d

15. In obstructive Jaundice a urine is dark (Conjugated bilirubin) b Gall bladder is always enlarged c Common bile duct is always enlarged d the liver is always enlarged

16 Advantage of MRI over CT a Better tissue resolution b better bone resolution c less expensive

17 WC of those is true for a new anaesthetic with high lipid stability a high potency b has fast onset of action c has slow onset of action d has slower elimination rate

18 Blindness WC is true
a Nutritional blindness is irreversible
b Glaucoma is irreversible
c Cataract irreversible
d Diabetic associated blindness is irreversible
NB Treatable

19 After a grafting WC of these returns first
a pain sensitivity b pressure c Temperature
d Motor function
NB in this order Pain before Touch before Temp and pressure discrimination

20 Branchial cyst arises from a 2nd branchial arch b 3rd branchial arch. c 2nd and 3rd branchial arch d 4th branchial arch
NB either 2nd 3rd branchial arch or 2nd branchial cleft.

21 Large w. cleavage line represent wr urgi
a Collagen collection. b Pleomorphic vessels
Capillaries.

22 Blisters are observed in a 1st degree burn b 2nd c 3rd d ~~the~~ All of the above

23 Papilloedema is a 2nd degree ~~pap~~ ophthalmopathy b 3rd c 1st d 4th
Seen fun

24 ~~Strain~~ Sign is for of
a DM b SS c Hypertension

25 Wr of these is not a for of Severe Non-proliferative a. DOT and blot haemorrhage
b Soft exudate c Neovascularization d Bleeding of AV vessels

26 Concerning Mannitol
a. It is a diuretic b antidiuretic c
c antihypertensive

27. Cephalosporin works via a Cell wall destruction b cell wall synthesis inhibition
c Nucleic blockade d Non of the above

NB disrupt synthesis of peptidoglycan

28 Multiple sign a uvula pulsation seen in aortic insufficiency (regurgitation) b throbbing seen in aortic valve regurgitation c pulsation felt artery in aortic regurgitation

NB

Musset sign – nodding of head
Quincke – Nail bed hyperaemia
Corrigan sign – rapid and forceful distension of arterial pulse
Shelley's sign – pulsation of the carotid

29 pathologic components of destroyed lung syndrome in TB except
a lung fibrosis b Bronchiectasis c lung abscess
5 fx

NB FBC^3 – fibrosis, Bronchiectasis, cystic lesions
– collapse, consolidation

30 wr of these is not a fx of paraneoplastic syndrome
a SIADH b c d

31 wr of these is a fx of cranial injury
a Battle sign b ~~otor~~ Rhinorrhea c Panda sign d Racoon sign e ring sign on paper

32 12/12 painful left hip in 58yr woman is best treated by a left hemi arthroplasty b left total hip replacement
NB If younger total is preferred

33 In Nerve injury wallerian degeneration does not occur in a Neuropraxia b Axonotmesis c Neurotmesis d None of the above

34. Bec of large cause massive haemoptysis a Fatal staining

NB Bubble Camp

- Bronchiectasis
- Aspergilosis
- TB, Tumor
- Lung Abscess, Embolism

Coagulopathy
Autoimmune dis
Fatal staining
Pneumonia

massive
- Presence of haemodynamic instability
-

35. Commonest hernia in female a Inguinal b. femoral c ~~Inguinoscrotal~~ Inguinovulva d Obturator

NB Inguinal is commonest in both sex but femoral occur more in female. but yet the have more occurrence of Inguinal just like the case of Salmonella typhi causing osteomyelitis in sickle but staph Aureus is still the commonest in them.

36. Valative sign:

NB perforated duodenal ulcer mimicking appendicitis.

is named after Ladyes guy author

37. Aside measles wc of these cause Mental retardation
a Yellow fever b Cytomegalovirus
c Rubella d

38 epiphyseal fracture is common in wc of the ff a elderly b adult c young
d children (Salter Harris fracture)

39 A px came in acute right chest pain and the jnr resident gave analgesics and antibiotics the px was relieved of the presentation and requested to be discharged (typical Uganda) but 24 hours after discharge the px represented with same R/L pain but the snr reg in duty noticed the diagnosis because
a the jnr reg gave analgesic too early b the antibiotic was given too early c the snr reg was not found d it was a new presentation

40 50yrs old man with progressive weakness of the limbs wc is not true
a. Test for Deep tendon reflex b CXR c Babinski
d Straight leg raising sign e DRE

41 Commonest cause of communicating hydrocephalus
a Meningitis b post ductal stenosis
c aqueductal stenosis d Arnold Chiari II

42. Commonest cause of non communicating hydrocephalus a aqueductal stenosis
b Meningitis c Dandy walker syndrome

43. Concerning aortic stenosis
a post ductal stenosis is most dangerous in adult

44. Sub arachnoid haemorrhage is best treated by a Burr hole and Drainage b Craniotomy and Evacuation c Conservative (Medscape plus check) d

NB Acute — AEE — Craniotomy and Evacuation
45. Xmic — CBD — Burr hole and Drainage

45. Complication of ventriculoperitoneal shunt
a Jejunal perforation b femoral perforation c ab dominal perforation

46 Paediatric tumour a 60-70% are in post-fossa b 40-50% are posterior fossa c 95% are in ant. fossa

NB
60% of paediatric tumour are in post. fossa
80% of CNS tumours are glioma
5% of glioma is oligodendrocyte and rare in children
Tumor of spinal cord affect children less commonly
Extramedullary tumour are usually more than intramedullary
- Ependymoma most common in adult
- Astrocytoma more common in children
- Meningioma affect women more commonly 75-80%
- CNS tum account for 20% of paediatric neoplasm

47. Commonest ulcers is a anterior b post. c middle
d None of the above.

48. Concerning H. pylori except
a. duodenal ulcer b Gastric ulcer c Gastritis
d Stress ulcer

49. Concerning Rhinorrhea

50. Concerning electrolyte urea balance a 32 es required per day b urine output 1500 c
d.

51 Concerning Meningocele (Myelo) a. Most associated with hydrocephalus b associated with club foot
Commonly c d
NB 1340 mls WT per day but 3L given because reduced faeces (200ml) body products (200ml)

52 Concerning club foot except
a fixe foot addiction b hind foot internal rotation
c hind foot equinus
NB EAVE
- Front foot - addiction
- hind foot - varus
- ankle - Equinus (horse hoof) walk with the toes
- Cavus - If calcaneous then walks on heel.

53 Mild Shock is a when px losses 5% of pcv b 10% of pcv c 15% of pcv d 20% of pcv
NB classified 15% or 750ml
mod II 15-30% 750-1500ml
Severe III 30-40% 1500-2000
very sev IV > 40 > 2000 mls

54. Concerning testicular torsion the golden hour a < 4 b < 8 c < 12 hrs d < 24 hrs

NB Cx undescended testis has risk of Torsion, Tumour, Trauma, Total loss of fertility in affected side

55 Best with ulcer best treatment options
a Combination chemotherapy b Radical mastectomy
c Radiation d Immunotherapy

NB CMF – Cyclophosphamide
– methotrexate
– 5FU
} given in 3 weekly for 6 cycles

TAC – Docetaxel + Adriamycin in 6 cycles

CAMF

56 ~~Concerning~~
Commonest cause of spinal injury is
a. fall from past b Road traffic accident
c Wrestling d Water sports

57. In trimodal model of polytraumatic pt the most death occur a Within 30 mins of accident b 6 hrs of accident c within 2 days d with 7 days

NB 50% of those that will die be in first few minutes
30% will die next 3 hours
others ≥ 3 wks

58 Acute intestinal obstruction a. If always need surgical intervention b always result

59. Which of these is not a sx of UMNL
a. hyperreflexia b hypertonia c hypotonia
d spasticity

60. Which of these is important in Chlorpheniramine's
a contraindicated use b use of alcohol

NB The Fs – Fair, fertile, female, fourty, fifty, fat.

61 Commest cause of intestinal obstruction in Africa a Inguinal hernia b Colonic ca

62. Commest causes of intestinal obstruction in Ikeri a Inguinal hernia

63. Which of these is associated with abd distention a undescended testis b hypertrophy c epi-central FTD

Triad of Prune Belly syndrome
NB – ~~[illegible]~~ absent abd wall muscle
– undescended testes
– dilated ureters or UTI

64 The cellular unit of breast
a acinus b alveolus c lobules

65. Commonest site of appendix a retrocaecal b. ileocaecal c ileoiliac d pelvic

* * * *

66 In trauma the adrenocorticotrophic stimulating hormone released is produced from
a. adrenal b hypothalamus c pituitary c pineal gland

67. A boy of 10 born with empty scrotum but one testis found in the superficial ring what is the best treatment
a. Give androgen hormone
b. watchful ~~[illegible]~~ waiting till puberty
c. Do orchidopexy of the testis
d. orchidectomy of the testis

68. One of these is not a cause of Testicular torsion
a. ectopic testis b large testis c horizontal lying testis d

69. Wz of these is responsible for blood contraction
a. Sympathetic nerve stimulation
b. Parasympathetic
c. pudendal nerve

70. Wz frequency do you use for both Rinne and Weber test
a. 256 b. 512 c

71. Concerning the spleen except
a. located 9–12 ribs
b. Stomach is ant to it
c. lies inf to the diaphragm

72. Wz of these should be given in children with cre
a. thiopental b c d

16yr. old medical student playing football on Azuri stadium fell and had dislocation of the shoulder

73 We dislocation is likely
a anterior b posterior c inferior d superior

74. We plain radiography view is most likely for the diagnosis
a. Bennett view b axillary view c AP view
d PA view

75. We of these is ineffective for sterilization
a γ ~~gas~~ wave b α-wave c Ethylene gas d

76. ~~Commonest cause of H~~ —
76. In ARM we of these is used as a delineating line
a levator ani muscle b transpyloric lines

77 We of these is not ~~in~~ in transpyloric plane
a ampulla of vater b hilum of the left kidney
c d
fixed retroperitoneal organs and the planes

78 Surgical infection (TB) is usually present with a lymphocytosis b Eosinophilia c monocytosis d

79. When dealing ankle joint fracture and dislocation head of up cos many questions come from it.

80. T-tube cholangiography is
a. done prior to see gall stone
b. done intraoperatively to view patency of bile duct c done post-op to view remnant stones post cholecystectomy.

81. Congenital malrotation of the gut
a. normally gut rotation is 270°
b. 270° anti clockwise
c 180° clockwise
d 180° anti clockwise
e 360°

82 Wr of these is xray for g ↑ ICP
a. erosion of sphenoid process
b. erosion of mastoid process
c Sutural diastasis

83 Pt presented with femoral swelling diagnosed to be femoral hernia, it will be treated
a. Inferior and lateral to pubic tubercle
b. superior and medial to pubic tubercle
c. lateral to the obturator furrow

84. Pt with testicular tumor on the left is checked for malignancy by sampling sentinel node
a. Paraaortic nodes
b prerenal node
c Inguinal nodes

85. The left testicular artery is a branch
a. external iliac b. renal artery c. aorta

86. Concerning Vitamin A wrong is true
a. VAD blindness is irreversible
b. common in developing than developed countries

87. Retrosternal extension of the thyroid checked in X-ray is ~~of~~
a. defect trachea deviation and compression
b. defect oesophageal deviation and compression
c. See effect on RLN

88 Wrong of these is not a contents posterior chest fascia
a. thyroid b. vagus c. oesophagus

89 Concerning SLN
~~89~~ a. supply the sternohyoid fascia
b. supply sternohyoid muscle
c. supply ~~sterno~~ omohyoid muscle

90. Wrong of these is true
a. foot supplied by L_4 and L_5
b. supplied by L_3
c. supplied by L_5 and S_1
d. supplied by S_1 and S_2

Q1 Child presented with reducible inguinal hernia of 7/7 ago but now irreducible what should be done
a. observe till he is of age
b do emergency exlap
c do herniotomy

Q2. A child presented with inguinal hernia but o/e it was discovered there was sac lateral to the spermatic duct and medial to it
a. partolin b Ritchie c Lotfres

Q3 Pt presented with acute pancreatitis with labs findings. use these to assess prognosis
Glucose < 6mmol/L
WBC 16000
AST 100 IU/L
LDH 1000 IU/L
a. 1% mortality b 10% c 0% d 20%

Q4. Incomp FAP
a autosomal recessive
b autosomal dominant
c mop premalignant
d mop based stay

95. Concerning hypospadias is/are false
a. Symphysis hypospadias is commonest cause
b. appendicular ca is commonest cause

96 28 year old fall on his hand and sustained Monteggian fracture we do treat
a. fracture of proximal ulna and ~~distal~~ proximal radius ulnar dislocation
b. fracture of proximal ulna and ~~proximal~~ distal radius ulnar dislocation
c
d

97. 34 yrs old trader sustained femoral shaft fracture on their way from market we 4 true
a. 1.5 – 2 ltr of blood may be lost
b. 2 – 3 ltr
c. 0.5 – 1 ltr
d. 3 – 4 ltr

98 Read up mode of its management many scenarios come from it

99 Implication that may arise
100 Typing fist ~~fixed~~ bony ~~fibrous~~ Tibiocalcaneous, tibiofibular etc

101 What form the joint

102 Concerning Hashimoto thyroiditis
a. usually hypothyroidism (NB calls phrase but early other)
b. associated with DM (NB autoimmune)
c common in caucasians

103 Post boundary of the breast is
a. P. major b. P. major c. L. dorsi

104 Wt of the heart is not affected in
a. prostate (~~osteo~~ sclerotic) b. Thyroid
c. kidney d. breast e. Lungs

105. Cancer Ca of the lip
a. most often in middle 1/3
b. most often lateral 1/3
c. most often at the side of the mouth

106 L. dorsi is supplied by wt nerve
a. long thoracic b. thoracodorsal

107. breast mass both pleural l/d axilla
is best treated with
a. radiotherapy b. combination chemotherapy
c. mastectomy d. immunotherapy

108 Concerning splenic injury
The stopping of the blood by pinching
the spleen is called.

109.

Manchester stage
1. Mass <5cm no lymph nodes
2. mass <5cm with mobile lymphnodes
3. >5cm with matted, fixed node
4. distant metastasis

Revision

Breast Ca. with peau d orange & lymphoedema

a. Breast Ca stage III (peau d'orange)

b. Swelling of the hand aka lymphoedema

c. Causes of b.

i. post irradiation (radiotherapy)

ii. malignant infiltration of axillary lymphatics

iii 2° to surgery

CMF - Doxorubicin 6 cycles
TAC 3 weekly for 6 cycles

d. Tx combination chemotherapy

CAMF - Cyclophosphamide, Adriamycin, Methotrexate, 5FU. CMF is mostly used.

Surgical ~~therap~~ Rx.

Simple mastectomy + axillary dissection ~~stage~~ (level 2).

Sites of metastases: Bones, Brain, lungs,

INV

I. FNAC II Core biopsy III Excisional biopsy (IV) Incisional biopsy (V) CXR (VI) FBC VII Mammography

fx of metastasis

I. Pulmonary symptoms of cough or dyspnoea

II axillary adenopathy without a palpable lump in the ~~(III) breast~~ breast.

III. Osseous deposit may cause bone pain especially back ache, pathologic fx especially of femur long bones eg skull, ribs or clavicle, cord compression

IV. hepatomegaly: Jaundice, ascites

2. Incisional hernia swelling around the umbilicus with incisional scar
- abnormality scan — umbilical swelling with the incisional scar
- Pediatrics fetus (incisional hernia)
- Wound dehiscence
- ↑ intra-abdominal pressure post-operatively (post op period for — hiccups, constipation, cough, straining for urinary difficulty and constipation
- Delayed wound healing from haematoma or infect or use absorbable suture
- obese pt because of ↑ intra-abd pressure
- Site of ~~defects~~ incision : the lower midline incision is weak because no aponeurosis behind the rectus muscle below the arcuate line
- Faulty technique, suture breaking or cutting out
- Congenital weakness of abd wall
- Foreign body eg suture.

Complications
- strangulation
- traumatic rupture of the atrophic skin with eversion of the contents
-

Femoral
- femoral herniorrhaphy
I. Lockwood
II. McEvedy
III. Lotheissen.

Rx.
Mesh repair (~~Mayo's repair~~).
~~Mayo's overlapping operation~~

- Stretch out scar in supra
- swelling underneath the scar
- hyperpigmentation, or hypopigmentation

Wound infection
- Chronic cough post op
- constipation, paralytic ileus

Clinical exam
- cough impulse
- Valsalva test
- (direct or indirect).

herniorrhaphy (modified Bassini)
complications
- Hems infect
- scrotal oedema
- Acute may infect inguinal.

Recurrent - Mesh repair of recurrent inguinal.

Proboscoid umbilicus

Complications of gastroschisis
- Serial Leading
- Deep leading
- Difficulty in ventilation
- Painful scarring
- Neuroma formation
- Stenosis w occlusion of jejunal vessels

3. Umbilical hernia
abnormality seen b. Rx c. indicator for surgery
- Umbilical swelling
protrusion through umbilical cicatrix
- Simple w mayo's repair overlapping operation
- ~~Pathophysiology~~

Indication for surgery.
- Strangulation
- Persistent hernia at 5 yrs (at age 5)
- Incarceration (irreducibility)
- rupture of the sac
- if defect > 1.5 cm in diameter

Predisposing factor
- Birth defects
- ↑ intra-abd pressure for
- umbilical infection
- Neonatal umbilical sepsis
- Congenital defect of umb. wall
- constipation
- multiple pregnancy
- obesity
- xmc cough
- umbilical sepsis

Complication
- Irreducibility
- Strangulation
- fistula formation
- rupture of hernia
- ulceration
- Bowel ~~predisposing factors~~
- pain xmc abd.
- failure
-

NB Omphalocele
Presence of gelatinous transparent sac covering the exviscerated abd contents. Layers lab AP
Wharton jelly, amniotic sac and peritoneum.

Inves
Prenatal u/s usually picked 18-20 weeks gestation.
AFP (α-feto protein usually ↑x > normal (omphalocele)
Echocardiography ↑x > normal (cardiac)
CXR
Karyotyping, RBC, Barium gram

(4) Flap
Indications b.wks 7 days before removing c.
Types of flap. — Groin flap — Superficial circumflex iliac artery
10-14 days before removing it
Indications for flaps
- Avascular area requiring bone or joint surgery
- ~~exposed~~ major blood vessel

I. Reconstruction of post laryngectomy defect
II. Reconstruction of a defect following removal of tumor
III. Reconstruction of paralysed facial muscle using functional free muscle flap

- Irradiated areas
- areas to undergo radiotherapy

Indication of flap

I. A very graftable bed
II. poorly vascularized Tx
III. for importance of vascularity esp
IV. prevention of recurrent xnic osteomyelitis

Complications

- Necrosis of flap
  - SSI
  - haematoma formation
  - Pain
  - loss of venous outlet

??

5 Barium Enema (Diverticulum).

Barium enema showing diverticulosis

Dx.

Colonic diverticulosis

5 also seen

Multiple outpouching of the ~~sigmoid~~ colon

CF

I. Painless rectal bleeding
II. flatulence III. abd bloating IV. Incomplete empty bowel
IV. Tenesmus

Rx. high fiber diet
bowel resection

Risk factors

- Increasing age
- Constipation
- Genetic predisposition

Surgical

Bowel resection and anastomosis
Hartmann's procedure.

Invest

Colonoscopy
plain AB X-ray
Contrast CT of Abdomen

Complications

- Diverticulitis
-

Risk factors

Aging, constipation, genetic predisposition, CT Dx
Diet

6. Cleft lip and palate

Predisposing factor

I. Vit A and B deficiency
II. Rubella, toxoplasmosis,
III. Irradiation
IV. Corticosteroids (Cortisol)
V. Drug like thalidomide

Abnormalities

I. Deviation and depression of ala of the affected nare
II. Deviation of nasal collumela
III. Hypoplasia of ala nasi of affected side
IV. If teeth then dental anomaly

Rx lip flaps of the ala nasi of unaffected.

- Mustard's mullard (Rotation of the medial element)
- Thompson straight advancement of lateral element to it.
- Tennison Randall triangular rep

Rx palate

- Von Lagenbeck
- Wardill Kilner procedure

Problem

- Feeding difficulty
- ~~Upper~~ respiratory tract infection eg otitis media
- Speech difficulty
- aspiration
- cosmetic effect
- Otitis media

Associated Anomaly.

- Undescended testis, heart defect, spina bifida, Omphalocele
- Stickler syndrome (for Complete)
- Pierre-Robin syndrome Complete
- Di George syndrome Complete.

7. Thyroid
- Demonstrated tracheal compressibility
- anaesthetic importance of this
  1. To anticipate difficult intubation in pt with thyroid enlargement
  II
  Other investigations to support this
  Neck X-ray to include thoracic inlet it will show compression or deviation of the trachea
  Operative Thyroidectomy
  Complications of procedure
- hypoparathyroidism
- hypothyroidism, keloid scar
- Recurrent laryngeal palsy
- Tension haematoma
- Laryngeal oedema
- Tracheomalacia
  } early
  Inv to differentiate
  Protrusion of tongue thyroid gland ~~[illegible]~~ inv

Von Lagenbeck, ~~[illegible]~~ Mordh Kilner - Probst

Early	Late
- Haematoma haemorrhage tension haematoma	- Keloid scar
- Respiratory obstruction 2°	- hypothyroidism
- Tension haematoma	- Recurrence
- Tracheomalacia	
- Laryngeal oedema	
- RLN palsy.	
- Surgical site infection	
- hypoparathyroidism	

Investigation
- Thyroid function test T_3, T_4
- Thyroid stimulating hormone TSH
- (I3) Thyroxine suppression test
- Thyroid releasing hormone stimulation
- USS

Computed Tomographic scan of brain
- biconvex hyperdense lesion
- effacement of lateral ventricle
- contralateral midline shift

lenticular
biconvexo convex
concavo convex

Acute haematoma — white
Sub acute — isodense
Xmic — dark

Acute epidural — biconvex — lenticular
Subd — Crescentric Concavo convex

Crenotomy + evacuation of haematoma of Acute

Xmic — Burr hole + drainage of haematoma

Shape tells the location — epidural ~ subd
density — Acute ~ xmic

x — simple intensified
x
x

Neurographic

GCS

Diversion ~~cerebrovascular~~ ventricular
resection + craniotomy

cleft lip and palate.
defect in upper lip extending from vermilion border of lip to floor of nose

- distance b/w two eye balls — hypertelorism
- Dental anomaly.

Dx
Unilateral Complete cleft lip.
Complete — floor of nostril

- Cosmetic
- feeding
- respiration
- aspiration speech defect

Rx. – Milward
– Temmison Randall
– Thompson (Rose – thompson)
– Lemmrissure

Palate
Van lagenbeck
furlow procedure

Associated syndrome
– Pierre Robin syn
– Treacher – Collins
– Dunn syn
– Edward
– Patau.

Redivac Drain

Active drain

Indications
– post thyroidectomy
– mastectomy
– post CRLF
– post ex laparotomy (esophagectomy, lapectomy)
– post cholecystectomy.

Advantage
i. quantifiable of exudate
ii. prevent sutures
iii.

MOA – –ve pressure suction

Disad
– cumbersome
– high negative pressure can injure tissue
– more expensive

Breast (Peau d'orange) + lymphoedema of arm.
1. malignant lymphatic infiltration
2. axillary venous thrombosis

Tx. lymphoedema — limb elevation

Tx. simple mastectomy + axillary dissection level 2.

complication: lymphangiosarcoma

* Tracheal carcinoma.
– often clinical – consolidation
– CXR chest radiography.
impossible anticipate of difficulty intubation.

8. a. Wound Dehiscence b. Entero Cutaneous fistula
c. Suturing technique d. predisposing factors to A.
e. appropriate suture f. Problems of B

Suturing technique

Simple Continuous
✓ like CC

Simple Interrupted



Predisposing factor to wound dehiscence 7-10 days, highest incidence in day 10

I. Surgical site infection (5-7) staph pyogenes.
II ↑ intra-abd pressure like post operative cough, vomiting and abd distention

III haematoma

appropriate suture
Non absorbable suture

Problems of Entrocutaneous fistula
- Malnutrition
- ↓ Immunity
- Dehydration
- Sepsis
- localized intra-abd abscess
- Peritonitis

Rx

Supportive
- Nutritional supplement
- antibiotic — Metronid, ceftriaxone
- fluid therapy
- wound dressing

Surgical
closure ≥ 4-8wk

Laparotomy.
Resection and bowel anastomosis
Psychological support

Q. Midline Neck Swelling
a. 2 differentials
b. clinical ctes to differentiate
c. Rx of each
d.

- Thyroglossal cyst
- lipoma

b. Protrusion of the tongue

c. Rx of each
Gustrunk operation
Thyroglossal cyst - complete excision
Lipoma excision

IV Redivac Drain
-ve Type of drain - closed drain and active
MUST high pressure

Post indications
I. ~~Post thyroidectomy~~ (leave after 48hr)
II. Post mastectomy
III. Typhoid perforation (post exploratory laparotomy)
IV. ORIF. post open reduction and internal fixation
V. ~~Appendicectomy (Appendectomy)~~ Post cholecystectomy

Keep Ad. — quantification of drainage
— Prevent spillage

Advs
- More expensive
- Cumbersome
- high pressure in tube faster

- Wound dry
- Prevent bacterial ~~contamination~~ ascension
- Allows evaluating volume ~~and rate~~ nature of fluid
- helps in early wound healing

2 Drain ~~tube~~ clipped by IS

11. Epidural needle (Tuohy needle)

Procedure: Epidural anaesthesia ~~Bacteria~~ epidural

parts: Epidural needle, catheter and filter

. Complications

i. post dural puncture headache

ii epidural haematoma

iii Epidural abscess

iv. arachnoiditis

v. post dural puncture hypotension

Indications

Caesarean

I Orthopedic surgery of lower limb including hips and pelvic

II Obstetric for CS (Caesarean section) (Caesarean sub

III Urology prostate and bladder surgery Prostatectomy urethroplasty

IV. Vascular surgery for lower limb amputation

V. General surgery like abdo surgery including hernia repair and appendectomy. herniorrhaphy

Contraindication

i ↑ Intracranial pressure

II Coagulopathy

III infection at site

IV Allergy to local anaesthetic

V Px refusal

- ~~post~~ ~~and~~ headache
- ~~post~~ ep.

subdural

CT in serious cases
- post small pituitary
- epidural hematoma
- epidural abscess
- arachnoid cysts
- post small pituitary

12. Pericardiocentesis

Indications
1. Cardiac tamponade
2. Pericardial effusion
3.

Contraindications
1. It must be from pericardial effusion
Presence of fibrous tissue
- aortic dissection

Complications
+ Coronary artery puncture / Coronary sinus
(II) haemothorax
III pneumothorax
IV. pneumopericardium
V. dysrhythmia
V. hepatic injury

- Infrasternal angle ~~xiphoid~~ or subxiphoid approach
- ~~for~~ through the 6th intercostal space at left sternal border or parasternal approach

& Levy

Ways of monitoring
I ~~Use~~ ~~guidance~~ Echocardiography
II. ECG
find: ECG or Echo
pericardiocentesis via angle of levy
III. Ultrasound

complications
- blood infusion
- by accidental
- ~~cist~~ leakage

13. Spinal bifida
Meningocele or Meningomyelocele
- Clinical ~~fx~~
- Abnormalities seen
- associated conditions

Presence of Hemaplacode
Swelling at midline of the lumbar region with Hemaplacode at the summit.

Clinical cp
- fluctuancy
- trans illuminate (+ in Meningocele)
- Myelomeningocele
- Meningocele

Associated Conditions
1 Arnold chiari malformation
Aqueductal stenosis 2 hydrocephalus
3. club foot
4. Sensory loss

Investigation
fetal USS in pregnancy

Management
- Cosmetics
- prevent rupture
- prevent cross infection

Take NB
VACTERLH.

Amniocentesis
III X-ray of the spine
IV. MRI & CT Scan

Aetiology
I. folic acid def in Pg
II Obesity
III Drug – anticonvulsant
IV. poorly managed diabetics
V. Extreme ages of pregnancy
VI. lowlighted parents
VII family Hx., previous Hx of child with spinal bifida
Prevention.

Complications of shunting
I. shunt infection
II shunt kinking
III obstruction
IV. migration
V. disconnection
VI. Gut perforation
VII intussusception
VIII volvulus
IX cst ascitis
X. peritonitis
XI inguinal hernia
XII CSF hydrocele
XIII intraventricular haem
XIV intracerebral bleeding
15 ventriculitis
16 encephalitis
17 meningitis
18 scalp abscess
19 osteomyelitis

I folic acid supp daily before conception
I



Rx
Multidisciplinary involving ~~urologist~~
- Urologist
- paediatric surgeon
- Otherpaedics

excision of placode
Duroplasty and closure

I ventricular dilatation both ventricles
II thinning of cortical posterior mantle.

Shunt series
Skull X-ray, lateral, AP
Abd X-ray AP & lateral
Cranial CT.

Complications
- Gut perforation
- shunt infection
-
-

Clinical fx
- Bladder and bowel incontinence
- abnormal eye movement
- Meningitis
- paralysis

Inv
- Cranial CT, cranial MRI
- Transfontanelle US

Tx
I ventriculoperitoneal shunt
II endoscopic 3rd ventriculostomy
III

Hydrocephalus
- Macrocephaly
- Sunshine eye appearance
- low set ears
- distended scalp veins

AD
- Hydrocephalus
- Sub galeal haema
- Sub dural
- hydrocephaly
- fanching cephaly
- Soto's syndrome

4. Xnic Osteomyelitis

I. Discoloration of skin
II. discharging sinus
III. Purulent discharge

- Shiny skin
- Healed wounds (ulcers)
- hyper pigmentation
- Depigmentation
- Discharging sinus (purulent ??)
- limb length discrepancy

Invest Radiography

1. X-ray of the limb AP and lateral showing knee and ankle joint
II. Radionuclear bone scan of limb
III. Blood culture
IV. Blood swab for MCS
V. ESR, CRP - Creatin phosphate
VI. MRI, CT, FBC

- Cortical thickening
- Cortical sclerosis
- loss of CM differentiation
- bone in bone appearance
- cloaca (X-ray) sinus
- clinical pic
-

Rx
Non-surgical
- Antibiotic 4 - 6wk (2wk IV 4wk oral) Belfast protocol

Surgery
Sequestrectomy, ~~Antibiotic~~
antibiotic impregnated bone cement to fill the space.

Complicat.
- Septic arthritis
- limb deformity
- pathological fracture
- malignant change

Causes
- Trauma
- vascular insufficiency - eg DM
- Haematogenous spread from septic focus
- Iatrogenic from previous surgery
- SCD
- Direct inoculation from penetrating wound

X-ray fx

1. Periosteal lifting w elevation
2. loss of cortico medullary differentiation
3. Subperiosteal incidency
4. Bone in bone appearance
5. Cortical thickening and sclerosis

DD
- VOC
- Septic arthritis
- cellulitis
- Thrombophlebitis

Test to confirm
Pen nothing test

- Rickets
- Skeletal dyschondroplasia
- Physical injury for osteomyelitis and knee
- Physical injury for trauma

Wind swing deformity: DJD, Blount (septic arthritis, injury, osteomyelitis)
- Rickets, physical injury
- Physiological Bowing (2-3 yrs)
- Blount (varum
- Skeletal dyschondroplasia

Angular deformity,
Unilateral Genu varum

(osteitis deformans

Causes
Poliomyelitis — Monostotic Paget's dx
Paget, osteomalacia, Blount's dx, malunion of the tibia fx
Pseudoarthrosis of tibia

Study
Investigations
X-ray of affected limb both knees AP, Lateral, x-ray of the unaff. limb
Serum Ca, Phosphate, ALP, albumin, Bone scan.
- Alkaline phosphatase
- Albumin

Rx
Correction tibia osteotomy, Counsel Comfort, Braces
medication vit D, Serum Ca.
physiotherapy
Other Rx
- Malunited fracture

x-ray
Splaying, cupping and fraying of metaphysis
radiolucent of epiphysis, ↑ both of epiphysis

15 Ear Discharge

Acute/Chronic otitis media

Rx
Aural toilet
IV antibiotic eg penicillin — Topical antibiotics — Ciprofloxacin, Gentamicin, Polymyxin B
Systemic decongestant eg Actifed
Anti histamine — Piriton

- Myringotomy
- Tympanoplasty

Complications
1. facial nerve palsy
2. Acute Mastoiditis
3. Meningitis
4. Brain and subdural abscess

- Pure tone Audiometry PTA
- Speech audiometry
- Conventional X-ray mastoid
- CT scan — Cholesteatoma, infiltration
MRI — Note lesion
Otoacoustic Emissions
Tuning fork

Bilateral
16 Nasal ~~Mass~~ mass

Epistaxis

DD.

i. Nasal polyps
ii Septal haematoma
iii Nasopharyngeal carcinoma (fibroangioma)

Presentation

- Epistaxis
- dyspnoea
- snoring
- mouth breathing
- obstructive sleep apnea
- OSA (obstructive sleep apnea)

Epistaxis

epistaxis
dyspnea
snoring
mouth breathing

Rx of DD.

polypectomy
Functional endoscopic sinus surgery (FESS) Nasal polyp

Sept haematoma
- ~~[illegible]~~ + antibiotic
Incision and drainage + antibiotic

Nasopharyngeal Ca.
Surgery, chemo, radio

- Pure tone audiometry (PTA)
- Speech audiometry
- Conventional radiography of mastoid
- Otoacoustic ~~emission~~
- Tuning fork

17. Fournier Gangrene.

Predisposing factors
1. Poor perineal hygiene
II malignancy
III Immunosuppression like HIV, DM
IV. Urinary incontinence.

Affected part
Testes.

Mgt
- IV fluids
- Nutritional debridement
- Injudicious dressing
- Analgesic
- Systemic antibiotics

18 Pterygium
fleshy growth in the cornea
Risk 2 causes
Prolonged exposure to sun, heat, wind and dust

Tx opt.
Medical Rx with eye drops, amniotic membrane transplant
Surgical excision
Laser therapy, conjunctival autografting
fleshy growth encroaching on the cornea

Complications
- Blindness (impairment of vision).
- Corneal scarring
- redness of eye
- Tearing of the eye
- dry itchy eye

19. Lymphoedema (Contd)

Causes

+ Cellulitis
II lymphatic filariasis
III DVT
Rx.

Castrunk procedure
Homan's procedure
Thomas
Charles procedure

Nrs: limb elevation
compression stocking
physiotherapy
Emphasis

- lymphangiosarcoma
- venous ulcers
- skin thickening
- Recurrent cellulitis

TB adenitis

1- Milroy's Dx
2- iatrogenic (surg. excision)
3- post mastectomy lymphoedema
4- DVT (Deep vein thrombosis)
5- lymphatic filariasis
6- surgical excision for node
7- hypoplasia or aplasia of lymphatic vessel

Invest
- Lymphangiography
- lymphoscintigraphy
- MRI of limb
- ESR Erythrocyte Sedimentation rate.

Rx

Cs

NB The oedema fluid is rich in PT as against oedema of heart and kidney failure we have low protein content.
Accumulation of fluid in interstitial space as consequent of defective lymphatic drainage.

- filariasis (lymphatic)
- pelvic tumor
- post surg to pelvic

Tx - Castrunk
Homan
Thomas
Charles

Emphasis

Endovenous laser ablation.

Rx. lysis of venous stripping
- cockett procedure

Varicose veins

Lateral - ss v (small sap)
medial - Great saphenous v

- ulcers
- bleeding
- Thrombophlebitis
- DVT

- Trendelenburg test
- Paris
- Tourniquet test

3

Haematuria

Greet, introduce yourself and ask
- Difficulty in passing
- Trauma
- occupation
- washing in H_2O
- flushing urine
  - Transfusion
  - Travelling for other prof
- Care so far
- abd massage
- associated pain

SC

- Alcoholic
- Cocaine
- Cassia
- Analgesic
- Cancer
- complaints
- care so far
- Contributing factors
- Family Hx and Social Hx

Metastasis

65yrs woman presenting with bloody stool and weight loss. Take focused Hx

GI symptoms

vomiting, abd pain, constipation, abd swelling, tenesmus (feeling of incomplete emptying of bowel)

pattern of meals for the ans during colorectal

Hx of Cancer (Asthma, Anaemia and appetite)

- loss of appetite
- Cough
- back pain

Hx of Cause

- Trauma
- haemorrhoid - ~~stool~~ freeze stem ~~Stem~~ with blood or
- anal fissure - pain on defecation
- PUD - upper abd pain
- passage of dark coloured stool
- rectal Ca - mucoid stool
- intussusception

CNS Hx of metastasis

- Yellow of eye
- blurred vision
- headache
- insomnia

Chest

cough, dyspnea, orthopnea, PND

Bone pain, pathological fracture.

Hx of cause

- What time you due and any improvement
-

Family Hx and social Hx.

- Aderators polyps, smoking and alcoholism
- past medical Hx.

CTSU

Take Hx in 3 yrs Man with Hx of difficulty in swallowing

Weight Cancer.

- oesophageal Ca
- Achalasia
- Traumatic stricture
- corrosive oesophagitis
- GERD
- foreign body impaction

Biodata NASORAM. Sex, occupation, Age.

PC

Dysphagia: onset, duration, liquid first or solid

achalasia — liquid first

Ca — solid first.

Onset

sudden —

Associated: Pain, hoarseness of voice, smelling in the mouth

Chest pain.

Cause.

Malignancy

Wt loss, loss of appetite

Achalasia

Chest pain, regurgitation, weight loss, cough

Trauma

Trauma to the neck

Corrosive

- debilitant ingestion of corrosive like acid
burning sensation in throat, vomiting
consumption of hot beverages.

GERD

abdominal fullness, upper abd pain

Foreign

Sudden cough in eating or choking

Oesophageal abscess

polytetra fractures in prog, blood cups,

Course

progression of symptoms

Complications

Dizziness, weakness, headache, coughing out of blood
chest pain

Case study

Past medical Hx.

Inflammatory, PUD, DM, SCD, HTN

Family

Hx of oesophageal Hx

Social. smoking, alcoholism

Hx weight loss and paraplegia.

Biodata: Age, sex, occupation

xtergies: Loss weight loss was noticed, sudden or gradual

paraplegia sudden, or progressive, incontinence, swelling on the back.

Causes

- Metastatic prostate Ca.
- Trauma spinal injury
- pott's Dx
- Spondylolisthesis
- Spinal cord compression signs.

- loss of appetite, back pain, swelling any part of the body
- pott, xmic cough, contact with adult with xmic cough, consumption of contaminated milk, might smear gave.

- Spinal compression - Early morning headache, tingling sensation in the limbs.

Trauma: Trauma to the back.

Course: Improvement or Worsening of symptoms.

emphysema, pounding, yellowness of eyes, back pain, cough

Cure so far: What have you done.

Past medical Hx. SHAPED
Sengue, HTN, Asthma, Epilepsy DM, Liver Investigation, prostate Ca.

Sexual

Consumption of alcohol, smoking, overcrowding

for anal malignancies - Bleeding
Pruritus
pain
discharge
palpable mass in anal canal.

Breast Lump.

Bridafa

Angina! When it was noticed, size, it is mobile,
Associates

Thyroid

'Bridafa'!

onset, duration, Wound, progression:
associated, difficulty in breating, breathing, fever, anxiety
Insomnia, heart intolerance, cold intolerance.

Causes

Thyroid cts: fever
TB adenitis
Malignancy

Eng

① Difficulty ~~with~~ dirn passing urine — Azithromycin
HGSS — Ciprofla
II 40yrs ~~with~~ pus discharge for leg
III

Clubs foot (Talipes Equinovarus)

- forefoot adduction
- hind foot varus
- Equinus deform
- Pes Cavus (high medial arch)

Tx. i. Ponseti manoeuvers
ii Percutaneous tenotomy of Achilles tendon.
iii posterior medial soft Tx release
iv. wedge calcaneal osteotomy.
v. Triple arthrodesis

Austin moore

Respiratory Gastrosis

Breast

- Intralesional excision
- Intralesional steroid injection
- low dose radiotherapy

- Genetic predisposition
- Black race (5x)
- sex (M:F = 1:1)
- pregnancy as priority.

chest

Intralesional steroid

Black race, familial, site

ear lobe, chin, nipple of neck, chest.

Contact

- Early physiotherapy
-

Cystic lymphangioma (lymphangioma)

- neck, axilla, retroperitoneal
- Intralesional sclerotherapy — Bleomycin
-

hypospadias

urethrovaginal fistula — urethroplasty

Complications

- ECF
- wound breakdown.

Haematuria
GIM.

- Difficulty in passing urine
- Trauma, occupation..
- washing in river
- Nocturia (stopping of urine)
- Transfusion Hx
- bleeding from other parts of the body
- Cut so far
- Co morbidity
- Abd mass / associated pain

Haematuria

Is initial, throughout or at the end? associated fever pain, Menses

Causes
Trauma.
- Injuries fract?
- Genotype
- Schistosoma
- Infarc cystic - hx pain - Stone or clot extended Hth hx.
- Bladder stone suprapubic discomfort
- Bladder calculi - Terminal bleeding with pain
- urethral lesion. bleeding independent of urine
- pulpulde dilated veins

— FUND, SHITT, weight loss, loss of appetite, transfusion, bleeding from other part of body.
Drugs.